

## OPEN REDUCTION AND K-WIRE FIXATION OF VERY LATE PRESENTING PAEDIATRIC SUPRACONDYLAR HUMERAL FRACTURES USING INVERTED V-Y TRICEPSPLASTY APPROACH AND CALLUS OSTEOCLASIS

Vidya Bhushan Singh<sup>1</sup>, Amit Kumar Chaurasia<sup>2</sup>, P. K. Lakhtakia<sup>3</sup>

<sup>1</sup>Assistant Professor, Department of Orthopaedics, Shyam Shah Medical College, Rewa, Madhya Pradesh.

<sup>2</sup>Associate Professor, Department of Orthopaedics, Shyam Shah Medical College, Rewa, Madhya Pradesh.

<sup>3</sup>Professor, Department of Orthopaedics, Shyam Shah Medical College, Rewa, Madhya Pradesh.

### ABSTRACT

#### BACKGROUND

Fracture supracondylar humerus is a common paediatric injury. The current preferred treatment option for the displaced supracondylar fracture is early closed reduction and percutaneous pinning. Neglected displaced fractures of supracondylar humerus are not uncommon in developing countries like India. We prospectively evaluated the results of early correction of 8 malunited paediatric supracondylar humeral fractures using inverted V-Y tricepsplasty approach and callus osteoclasia (Calloclasis).

#### MATERIAL AND METHODS

This prospective study included 10 extension type malunited paediatric supracondylar fractures that were operated from July 2012 to June 2014. Exposure of the distal humerus was done using inverted V-Y tricepsplasty approach. The entire callus tissue was circumferential removal, anatomic reduction of the displaced bony fragments was achieved and then fixation with two Kirschner wires was done. K-wires were removed at around 4<sup>th</sup> week postoperatively and patients were followed up monthly up to the 6 months.

#### RESULTS

All fractures united in a mean duration of 7.4 weeks. At last follow-up after 5 months on average, 7 (87.5%) patients had satisfactory outcomes. Iatrogenic ulnar neuropraxia was found in 1 patient and restricted range of motion was noted in 1 patient.

#### CONCLUSION

The advantages of V-Y tricepsplasty approach is that it is simple and allows doing a circumferential callus osteoclasia, which helps in reducing and fixing the fracture under direct visual control. The disadvantage of this approach is that it is associated with more postoperative pain and requires prolonged triceps rehabilitation.

#### KEYWORDS

Supracondylar Humeral Fractures, Osteoclasia, Tricepsplasty.

**HOW TO CITE THIS ARTICLE:** Vidya Bhushan Singh, Amit Kumar Chaurasia, P. K. Lakhtakia. "Open Reduction and K-Wire Fixation of Very Late Presenting Paediatric Supracondylar Humeral Fractures Using Inverted V-Y Tricepsplasty Approach and Callus Osteoclasia." *Journal of Evolution of Medical and Dental Sciences* 2015; Vol. 4, Issue 95, November 26; Page: 16080-16083, DOI: 10.14260/jemds/2015/2349.

#### INTRODUCTION

Supracondylar humeral fractures (SCHF) are common paediatric injuries representing the most frequent fractures in children less than 8 years of age and the most common elbow fractures.<sup>1,5</sup> These fractures are classified using the modified Gartland classification and most of them are of extension type.<sup>6,7</sup> Currently, the preferred approach for the treatment of displaced paediatric supracondylar fractures is early closed reduction and percutaneous pinning. If attempts at closed reduction fail, then open reduction of the fracture followed by cross-pinning should be considered. Neglected displaced fractures of supracondylar humerus are not uncommon in developing countries.

The main reasons for the delayed presentation are lack of medical facilities or social and financial constraints and therefore patients have to initially seek treatment from bonesetters who immobilize the elbow in extension. This result in malunion and shortening of triceps thus makes late reduction more difficult.<sup>8</sup> Surgical exposure can be accomplished by a variety of approaches. There is no clear evidence in the literature regarding which of the surgical approaches brings about the best outcomes as well as minimizing complications.<sup>9,11</sup> We prospectively evaluated the results of very late open reduction of 8 malunited paediatric supracondylar humeral fractures using inverted V-Y tricepsplasty approach and callus osteoclasia (Calloclasis).

#### MATERIALS AND METHODS

This prospective study was carried out from July 2012 to June 2014. The study included all the patients of neglected fractures of supracondylar humerus who presented after 1 month of the initial trauma (Fig-1 and 2). We operated 10 paediatric supracondylar fractures and all were extension-type (1 Gartland type II and 7 Gartland type III displaced fractures).

*Financial or Other, Competing Interest: None.*

*Submission 08-11-2015, Peer Review 09-11-2015,*

*Acceptance 16-11-2015, Published 26-11-2015.*

*Corresponding Author:*

*Dr. Vidya Bhushan Singh,*

*F-10, Doctor's Colony,*

*S. S. Medical College Campus,*

*Rewa, Madhya Pradesh, India.*

*E-mail: dr.vidyabhushan.singh@gmail.com*

*DOI:10.14260/jemds/2015/2349.*

All patients had taken initial treatment either in the form of manipulation by any bonesetter or a trial of reduction and above elbow slab application in some private clinic and presented to us late. We excluded patients with flexion-type fractures, compound fractures, cases presented very late after 3 months of initial injury. Out of 10 operated cases, we excluded 2 patients from the study who lost in follow-up. Fall while playing and fall from a height were the predominant modes of injury.

All the patients in this study were treated by open reduction and internal fixation (ORIF). The procedure was done under general anaesthesia with the patient taken in lateral position. The tourniquet inflated and a midline straight skin incision was made. The ulnar nerve was safely exposed and separated. Exposure of the distal humerus was done using inverted V-Y tricepsplasty approach (Proximally based triceps tongue), so that the supracondylar region could be circumferentially reached.

The fractures were found almost united, though they were not remodelled. The entire callus tissue was circumferential removal from the underlying original supracondylar area to expose the fracture ends. Manipulation and anatomic reduction of the displaced bony fragments was achieved and then fixation with at least two crossing Kirschner wires was done under direct vision.

Thus complete correction of the deformity and full range of movement of the elbow joint was achieved intraoperatively (Fig-3). After the triceps repair and skin closure, an above elbow slab was applied in approximately 20 to 30 degrees of elbow flexion. Slab was removed at 2<sup>nd</sup> week and active range of motion exercises was started. K-wires were removed at around 4<sup>th</sup> week postoperatively. Regular follow-up (Clinical and radiological) was done monthly up to the 6 months. The functional outcome was assessed using Flynn criteria.<sup>12</sup> Excellent, good and fair outcomes were considered satisfactory (Table-1).

Outcome	Loss of Carrying Angle (°)	Loss of Motion (°)
Satisfactory		
• Excellent	0-5	0-5
• Good	6-10	6-10
• Fair	11-15	11-15
Unsatisfactory		
• Poor	>15	>15

**Table-1: Grading System developed by Flynn et al.**

## RESULTS

All fractures united in a mean duration of 7.4 weeks (Range 5–10 weeks). Analysis of the results showed that the younger the patient the faster the union, and the earlier the intervention (Injury–surgery interval) the faster the union. At last follow-up after 5 months on average (Range: 3–6 months), the outcome was excellent in 2(25%) patients, good in 3(37.5%), fair in 2(25%), and poor in 1(12.5%). Thus, 7(87.5%) patients had satisfactory outcomes (Fig-4 and 5).

Postoperative complications occurred in 1 patient, consisting of iatrogenic ulnar neuropraxia in 1 patient due to intra-operative nerve stretching that resolved within 4 months.

Restricted range of motion was noted in 1 patient, who had severely displaced malunited fracture and underwent very late open reduction and resulted in loss of more than 25° of extension and more than 20° of flexion. No case of compartment syndrome was recorded.

## DISCUSSION

Extension-type supracondylar fractures are the most common elbow fractures in children. Classically, prompt reduction and percutaneous pinning is the method of choice.<sup>13,16</sup> According to the literature, neglected supracondylar humeral fractures are those who are more than 14 days old and have already started the biological process of healing with early callus formation.

Late presentation of displaced supracondylar humeral fracture in a child is common in developing countries. In our study, we included very late presenting cases that had injury 1 to 3 months old. Tiwari et al. in India.<sup>17</sup> and Abdullah et al. in Turkey,<sup>8</sup> reported mean treatment delays of 4 and 6 days, respectively. A study by Lal and Bhan.<sup>18</sup> included 20 children with delayed open reduction by means of a posterior approach for supracondylar humeral fractures. The delay time ranged from 11 to 17 days. In another study by Abdullah et al.,<sup>8</sup> the average delay time was 6 days (Range 2–19 days). In our study, inability of treating physician to achieve a satisfactory closed reduction due to continued swelling (5 cases) was the main reason for the fracture displacement in an above elbow slab and malunion. The rate of conversion to open reduction has been reported as ranging from less than 3% to about 46%.<sup>19</sup>

The second most common reason for late presentation of the fracture supracondylar humerus (In 3 cases) was that patients first consulted bonesetters who used massage, forcible manipulations and immobilisation in extension. The above approaches delayed the diagnosis and treatment. The average time for complete union in the current study was 7.2 weeks (Range 5–10 weeks) that is comparable to a study by Dehao et al.<sup>20</sup>

In our study, the time to regain the near normal ROM ranged from 12 to 22 weeks with a mean duration of 16 weeks with faster recovery in patients with faster union and less immobilization. In the study by Eren et al.<sup>8</sup> full functional recovery was achieved within 3 months in 29 patients (93.5%). Explanation for inferior functional result could be very late presentation (After 1 month) and extensive soft tissue dissection (Tricepsplasty). The advantages of V-Y tricepsplasty approach is that it allows to do a circumferential callus osteoclasts, which helps in reducing and fixing the fracture under direct visual control.<sup>21</sup> Although the V-Y tricepsplasty is simple, this procedure has its disadvantages and it leads to more pain after surgery and an extension deficit. Recovery is slow and requires patients to be highly motivated to complete the required rehabilitation.<sup>22</sup>

## REFERENCES

- Ozkoc G, Gonc U, Kayaalp A, Teker K, Peker TT. Displaced supracondylar humeral fractures in children: open reduction vs. closed reduction and pinning. Arch Orthop Trauma Surg. 2004;124:547–551.

2. Kaewpornsawan K. Comparison between closed reduction with percutaneous pinning and open reduction with pinning in children with closed totally displaced supracondylar humeral fractures: a randomized controlled trial. *J Pediatr Orthop B*. 2001;10:131–137.
3. Aronson DC, Vollenhoven E, Meeuwis JD. K-wire fixation of supracondylar humeral fractures in children: results of open reduction via a ventral approach in comparison with closed treatment. *Injury*. 1993;24:179–181.
4. Cramer KE, Devito DP, Green NE. Comparison of closed reduction and percutaneous pinning versus open reduction and percutaneous pinning in displaced supracondylar fractures of the humerus in children. *J Orthop Trauma*. 1992;6:407–412.
5. Omid R, Choi PD, Skaggs DL. Supracondylar humeral fractures in children. *J Bone Joint Surg Am*. 2008;90:1121–1132.
6. Gartland JJ. Management of supracondylar fractures of the humerus in children. *Surg Gynecol Obstet*. 1959;109:145–154.
7. Barlas K, George B, Hashmi F, Bagga T. Open medial placement of Kirschner wires for supracondylar humeral fractures in children. *J Orthop Surg (Hong Kong)* 2006;14:53–57.
8. Abdullah Eren, Güven Melih, Erol Bülent, Çakar Murat. Delayed surgical treatment of supracondylar humerus fractures in children using a medial approach. *J Child Orthop*. 2008;2(1):21–27.
9. Ay S, Akinci M, Kamiloglu S, Ercetin O. Open reduction of displaced pediatric supracondylar humeral fractures through the anterior cubital approach. *J Pediatr Orthop*. 2005;25:149–153.
10. Rasool MN, Naidoo KS. Supracondylar fractures: posterolateral type with brachialis muscle penetration and neurovascular injury. *J Pediatr Orthop*. 1999;19:518–522.
11. Pretell Mazzini J, Rodriguez Martin J, Andres-Esteban EM. Surgical approaches for open reduction and pinning in severely displaced supracondylar humerus fractures in children: a systematic review. *J Child Orthop*. 2010;4(2):143–152.
12. Flynn JC, Matthews JG, Benoit RL. Blind pinning of displaced supracondylar fractures of the humerus in children: sixteen years' experience in long-term follow-up. *J Bone Joint Surg Am* 1974;56:263–72.
13. Loizou CL, Simillis C, Hutchinson JR. A systematic review of early versus delayed treatment for supracondylar humeral fractures in children. *Injury* 2009;40:245–8.
14. Yildirim AO, Unal VS, Oken OF, Gulcek M, Ozsular M, Ucaner A. Timing of surgical treatment for type III supracondylar humerus fractures in pediatric patients. *J Child Orthop* 2009;3:265–9.
15. Mehlman CT, Strub WM, Roy DR, Wall EJ, Crawford AH. The effect of surgical timing on the perioperative complications of treatment of supracondylar humeral fractures in children. *J Bone Joint Surg* 2001;83:323–7.
16. Kazimoglu C, Cetin M, Sener M, Agus H, Kalanderer O. Operative management of type III extension supracondylar fractures in children. *Intern Orthop* 2009;33:1089–94.
17. Tiwari A, Kanojia RK, Kapoor SK. Surgical management for late presentation of supracondylar fracture in children. *J Orthop Surg* 2007;15:177–82.
18. Lal GM, Bhan S. Delayed open reduction for supracondylar fractures of the humerus. *Int. Orthop* 1991;15(3):189–191.
19. Dehao Fu, Xiao Baojun, Yang Shuhua, Jin Li. Open reduction and bioabsorbable pin fixation for late presenting irreducible supracondylar humeral fracture in children. *Int Orthop* 2011;35(5):725–730.
20. Peters CL, Scott SM, Stevens PM. Closed reduction and percutaneous pinning of displaced supracondylar humerus fractures in children: description of a new closed reduction technique for fractures with brachialis muscle entrapment. *J Orthop Trauma* 1995;9:430–434.
21. Mahaisavariya, W. Laupattarakasen Neglected dislocation of the elbow *Clin Orthop* 2005;431:21–25.
22. B. Mahaisavariya, L. Laupattarakasen, A. Supachutikul, H. Taesiri, S. Sujaritbudhungkoon. Late reduction of dislocated elbow need triceps be lengthened? *J Bone Joint Surg Br* 1993;75:426–428.

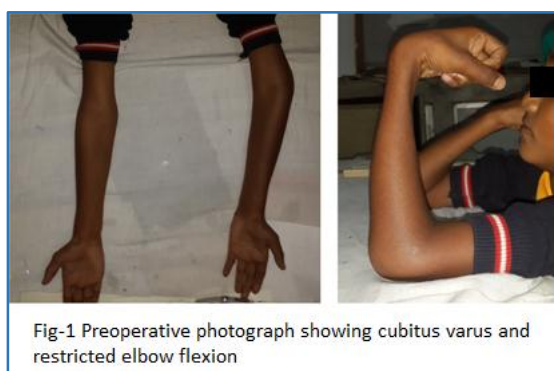

Fig-1 Preoperative photograph showing cubitus varus and restricted elbow flexion

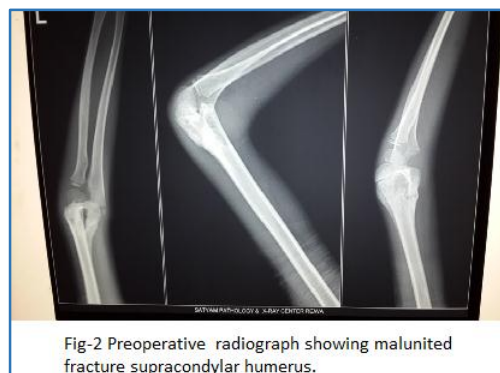

Fig-2 Preoperative radiograph showing malunited fracture supracondylar humerus.

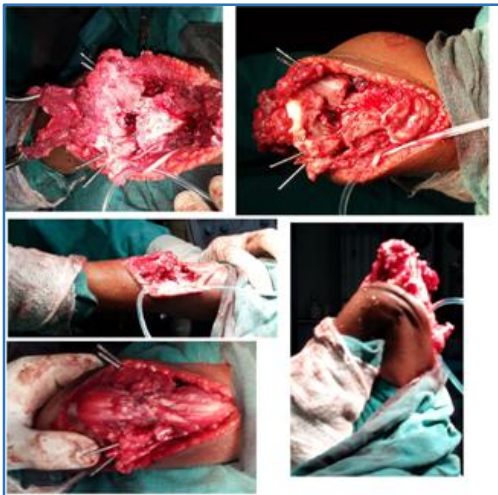


Fig 3 intraoperative photographs showing distally based triceps triceps tongue, callus osteoclasts, fracture reduction, k wire fixation, confirmation of full ROM

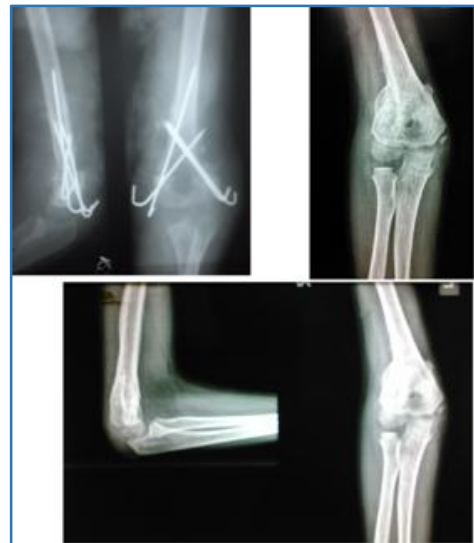

Fig-4 Radiograph of Immediate postop period and follow up at 6th month.



Fig 5- Follow up photographs at 6th month postop showing near normal ROM at elbow.